Excimer laser coronary atherectomy in septal collaterals during retrograde recanalization of a chronic total occlusion

Marc-Alexander Ohlow,[1] Ullrich Lotze,[2] Bernward Lauer[1]

[1]Department of Cardiology, Zentralklinik Bad Berka, Bad Berka; [2]DRK-Krankenhaus, Sondershausen, Germany

Abstract

Management of chronic total occlusions has been refined through the development of a retrograde approach via collateral pathways. We describe here the use of excimer laser coronary atherectomy in the septal collaterals. This appraoch was not yet described in the literature.

Case Report

A 63-year old male with a history of stable angina class CCS III (Canadian Cardiovascular Society) was admitted to our hospital for recanalization of a chronic total occlusion (CTO) of the right coronary artery (RCA) (Figure 1). Initially, we attempted an antegrade recanalization of the CTO with a non-hydrophilic wire (Asahi, Japan). Unfortunately, it was not possible to cross the heavily calcified occlusion. We engaged the left coronary artery with a short 6 F Judkins left 4 guiding catheter. Although there were only tiny septal collaterals present (Figure 2), we passed a hydrophilic coated wire (Runthrough NS, Asahi, Japan) into the distal RCA. However, it was neither possible to pass a microcatheter (Quick Cross, Spectranetics, USA) nor a balloon (Avion 1.25 mm, Invatec, USA) through the septal collaterals. We enlarged the collaterals with the Point 9 X-80 laser catheter Vitesse rapid exchange (Spectranetics, USA) with a total amount of 4,305 pulses delivering up to 80 mJ/mm² at repetition rates of between 25 and 80 Hz (Figure 3). The retrograde guide wire and balloon could now be advanced easily to the proximal part of the RCA. The CTO could be penetrated with a hydrophilic guide wire (Confianza Pro 9, Asahi, Japan) and three Everolimus-eluting stents (Xience V, Abbot, USA) were implanted (Figure 4).

Correspondence: Marc-Alexander Ohlow; Department of Cardiology, Zentralklinik Bad Berka, Robert-Koch-Allee 9, 99437 Bad Berka, Germany.
Tel. +49.36458.541216 - Fax: +4936458.53605.
E-mail: marc.ohlow@zentralklinik.de

Key words: chronic total occlusion, retrograde recanalization, excimer laser coronary atherectomy.

Contributions: all authors are responsible for study conception and design, analysis and interpretation of data, drafting the article or revising it critically for important intellectual content, and final approval of the version to be published.

Conflict of interest: the authors report no conflicts of interest.

Received for publication: 11 May 2011.
Revision received: 26 September 2011.
Accepted for publication: 25 October 2011.

Heart International 2011; 6:e8
doi:10.4081/hi.2011.e8

Discussion

Recently, management of CTOs has been refined through the development of a retrograde approach via collateral pathways. The current success rate of retrograde recanalization of up to 60-85%[1,2] was mainly driven by advances in the technique and the development of materials. Techniques which have been improved include landmark wire, kissing wire, and controlled antegrade and retrograde subintimal tracking (CART). Materials which have been further developed include hydrophilic/polymer coating of guide wires

Figure 1. Occluded right coronary artery.

Figure 2. Selective visualization of the septal collaterals (arrow) with a microcatheter (Quick cross, Spectranetics, USA).

Figure 3. Enlargement of the septal collaterals with an excimer laser (arrow) (9 X-80 laser catheter Vitesse rapid exchange; Spectranetics, USA).

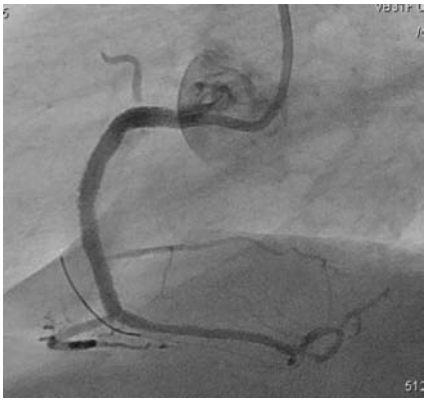

Figure 4. Final result after recanalization of the occluded right coronary artery and implantation of 3 drug-eluting-stents.

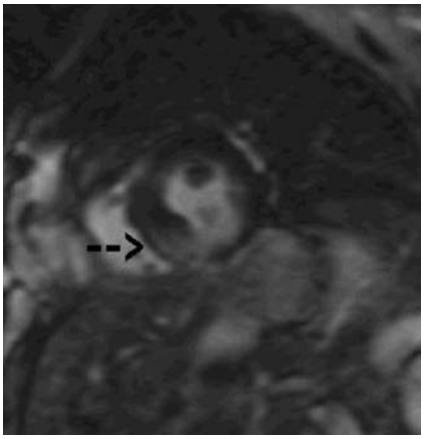

Figure 5. Magnet resonance imaging of the interventricular septum demonstrating local contrast accumulation (arrow).

and greater wire stiffness and torquability, as well as short guiding catheters, micro catheters, and balloon sizes less than 1.5 mm in diameter with very small entry profiles. However, passing septal collaterals with material other than wires is not possible in some cases. By using the Point 9 X-80 laser catheter we were able to obtain an encouraging result without evidence of major damage in the interventricular septum, as demonstrated by follow-up MRI (Figure 5).

Excimer lasers were invented in the mid-1970s.[3] They produce intense flashes of ultraviolet light that allow the vaporization of shallow layers of tissue or plaque, typically a few microns in depth.[4] Excimer laser coronary atherectomy (ELCA) was introduced in the 1980s as an alternative method of angioplasty,[5] and represents a therapeutic option for lesions which are non-dilatable or which cannot be crossed with balloon angioplasty.[4]

The Point 9 X-80 xenon chloride excimer laser catheter is a pulsed ultraviolet laser catheter. It differs from longer-wavelength continuous-wave lasers in that it causes minimal thermal injury to tissue and is capable of ablating calcified plaque. Early generation 1.6-mm catheters were made of twelve 100-µm fibers. The 0.9 mm consisted of two rows of 27 50-µm fibers arranged concentrically around the PTFE (polyflourethylene) walled guide wire tubing. Histological studies on animal tissue *in vitro* and in live porcine lesion models, along with subsequent clinical investigations showed that this catheter is safe and effective in patients with complex and/or balloon resistant lesions.[6,7] The use of the Point 9 X-80 laser catheter to open up the septal collaterals facilitating the passage of balloons and stent into the distal parts of the occluded artery is experimental. However, this option has to be tested further but might provide an alternative approach in selected cases of retrograde recanalization.

References

1. Colmenarez HJ, Escaned J, Fernandez C, et al. Efficacy and safety of drug-eluting stents in chronic total coronary occlusion recanalization: a systematic review and meta-analysis. J Am Coll Cardiol 2010;55:1854-66.
2. Chung SH, Kim MH, Yu LH. Initial experience of retrograde wire approach in coronary chronic total occlusion intervention. Korean Circ J 2009;39:228-35.
3. Ewing J, Brau C. Laser action on the 2S+1/2 – 2S+1/2 bands of KrF and XeCl. Appl Phys Lett 1975;27:350-2
4. Taylor K, Harlan K, Branan N. Small 0.7 diameter laser catheter for chronic total occlusions, small vessels, tortuous anatomy, and balloon resistant lesions – development and initial experience. EuroIntervention 2006;6:265-9.
5. Litvack F, Eigler N, Margolis J, et al. Percutaneous excimer laser coronary angioplasty: results in the first consecutive 3,000 patients. The ELCA investigators. J Am Coll Cardiol 1994;23:323-9
6. Taylor K, Papaioannou T, Harlan K, et al. Small excimer laser angioplasty for fibrocalcified tissue penetration. Laser Surg Med 2000;26:10.
7. Contreras G, Cieza T, Hardy N, et al. Uncrossable coronary obstruction treated by the new laser guidewire. J Invas Cardiol 2005;17:560-2.